

Light-Chain (AL) Amyloidosis: Diagnosis and Treatment

Vaishali Sanchorawala

Department of Medicine, Section of Hematology/Oncology, Boston University Medical Center, Boston, Massachusetts

Light-chain (AL) amyloidosis is the most common form of systemic amyloidosis and is associated with an underlying plasma cell dyscrasia. The disease often is difficult to recognize because of its broad range of manifestations and what often are vague symptoms. The clinical syndromes at presentation include nephrotic-range proteinuria with or without renal dysfunction, hepatomegaly, congestive heart failure, and autonomic or sensory neuropathy. Recent diagnostic and prognostic advances include the serum free light-chain assay, cardiac magnetic resonance imaging, and serologic cardiac biomarkers. Treatment strategies that have evolved during the past decade are prolonging survival and preserving organ function in patients with this disease. This review outlines approaches to diagnosis, assessment of disease severity, and treatment of AL amyloidosis.

Clin J Am Soc Nephrol 1: 1331–1341, 2006. doi: 10.2215/CJN.02740806

The amyloidoses are a group of diseases that have in common the extracellular deposition of pathologic, insoluble fibrils in various tissues and organs. The fibrils have a characteristic β -pleated sheet configuration that produces apple-green birefringence under polarized light when stained with Congo red dye. Many different proteins can form amyloid fibrils, and the types of amyloidosis are classified on the basis of the amyloidogenic protein as well as by the distribution of amyloid deposits as either systemic or localized (1). In the systemic amyloidoses, the amyloidogenic protein is produced at a site that is distant from the site of amyloid deposition. In contrast, in localized disease, the amyloidogenic protein is produced at the site of amyloid deposition.

Light-chain (AL) amyloidosis is the most common type of systemic amyloidosis. Although AL amyloidosis typically is viewed as a rare disease, its incidence is similar to that of Hodgkin's lymphoma or chronic myelogenous leukemia (2). It is estimated to affect five to 12 people per million per year, although autopsy studies suggest that the incidence might be higher (3). The amyloidogenic protein in AL amyloidosis is an Ig light chain or a fragment of a light chain that is produced by a clonal population of plasma cells in the bone marrow. The plasma cell burden in this disorder is low, typically 5 to 10% (4), although in approximately 10 to 15% of patients, AL amyloidosis occurs in association with multiple myeloma (5).

Several advances during the past decade have had a substantial impact on the approach to treatment and the prognosis of AL amyloidosis. This review focuses on diagnosis, assessment of organ involvement, and treatment of the disease. Treatments that aim to induce hematologic remissions to improve patient

survival and the function of affected organs, as well as aspects of symptomatic treatment that are relatively unique to this disease are presented.

Pathogenesis

A detailed elaboration of the pathogenesis of AL amyloidosis is beyond the scope of this article, but a few points warrant discussion. A key feature of all types of amyloidosis is abnormal folding of a protein that is normally soluble (6). In AL amyloidosis, the abnormal folding is the result of either a proteolytic event or an amino acid sequence that renders a light chain thermodynamically unstable and prone to self-aggregation. The aggregates form protofilaments that associate into amyloid fibrils (7). In all types of amyloidosis, glycosaminoglycan moieties of proteoglycans and serum amyloid P (SAP) (8) protein interact with the amyloid fibrils or deposits, promoting fibril formation and stability in tissue (6). Organ dysfunction results from disruption of tissue architecture by amyloid deposits. However, increasing evidence indicating that amyloidogenic precursor proteins or precursor aggregates have direct cytotoxic effects that also contribute to disease manifestations is emerging (9).

In AL amyloidosis, the clonal plasma cells express light chains of the λ isotype more frequently than the κ , with a ratio of approximately 3:1, despite the greater proportion of κ than λ expressing plasma cells in a normal bone marrow. The Ig light-chain variable region (VL) genes that are expressed by AL clones include several that are expressed less frequently in the normal repertoire, indicating that germline-encoded features may contribute to the propensity of certain subtypes of light chains to form amyloid. Evidence of antigen-selective pressure on amyloidogenic VL genes as well as homogeneity of somatic mutations support the concept that the monoclonal transformation of most amyloidogenic plasma cells occurs after B cell maturation and clonal selection in the lymphoid follicle (10). Associations between Ig VL germline gene use and amyloid-

Published online ahead of print. Publication date available at www.cjasn.org.

Address correspondence to: Dr. Vaishali Sanchorawala, Boston Medical Center, 88 East Newton Street, Boston, MA 02118. Phone: 617-638-7523; Fax: 617-414-1831; E-mail: vaishali.sanchorawala@bmc.org

related organ involvement have been described by several groups. This organ tropism may be related to the antigenic affinities of the clonal light chains (11).

Clinical Presentations

The organs that most frequently are affected in AL amyloidosis are the kidneys and the heart (5,12); however, virtually any tissue other than the brain can be involved. Kidney involvement usually presents as nephrotic syndrome with progressive worsening of renal function. In a small proportion of patients (approximately 10%), amyloid deposition occurs in the renal vasculature or tubulointerstitium, causing renal dysfunction without significant proteinuria (13). Amyloid deposition in the heart results in rapidly progressive heart failure because of restrictive cardiomyopathy. The ventricular walls are concentrically thickened with normal or reduced cavity size. The ventricular ejection fraction can be normal or only slightly decreased, but impaired ventricular filling limits cardiac output (12). Low voltage on the electrocardiogram is found in a high proportion of patients and often is associated with a pseudo-infarct pattern (12). Hepatomegaly is common and can occur as a result of either congestion from right heart failure or amyloid infiltration of the liver. Hepatomegaly from amyloid infiltration can be massive, and on physical examination, the liver typically is “rock hard” and nontender. Profound elevation of alkaline phosphatase with only mild elevation of transaminases is characteristic of hepatic amyloidosis because infiltration occurs in the sinusoids (14). Autonomic nervous system involvement by AL amyloidosis can lead to orthostatic hypotension, early satiety as a result of delayed gastric emptying, erectile dysfunction, and intestinal motility issues. Painful, bilateral, symmetric, distal sensory neuropathy that progresses to motor neuropathy is the usual manifestation of peripheral nervous system involvement. Soft tissue involvement is characterized by macroglossia, carpal tunnel syndrome, skin nodules, arthropathy, alopecia, nail dystrophy, submandibular gland enlargement, periorbital purpura, and hoarseness of voice. Although present in a minority of patients, macroglossia is a hallmark feature of AL amyloidosis. Endocrinopathies such as hypothyroidism and hypoadrenalism are rare but are reported to occur with AL amyloidosis as a result of amyloid infiltration of the glands (5).

Diagnosis

The nonspecific and often vague nature of symptoms that are associated with AL amyloidosis frequently leads to delays in diagnosis such that organ dysfunction is advanced by the time treatment is initiated. The diagnosis of AL amyloidosis should be considered in patients with unexplained proteinuria, cardiomyopathy, neuropathy, or hepatomegaly and in patients with multiple myeloma that has atypical manifestations.

The diagnosis of AL amyloidosis requires (1) demonstration of amyloid in tissue and (2) demonstration of a plasma cell dyscrasia. Tissue amyloid deposits demonstrate apple-green birefringence when stained with Congo red and viewed under polarizing microscopy. Fine-needle aspiration of abdominal fat is a simple procedure that is positive for amyloid deposits in >70% of patients with AL amyloidosis (15,16). Other tissues

that allow for relatively noninvasive biopsy procedures are the minor salivary glands, gingiva, rectum, and skin. However, obtaining tissue from an affected organ may be necessary to establish the diagnosis of amyloidosis.

Once a tissue diagnosis of amyloidosis has been established, confirmation of AL disease requires demonstration of a plasma cell dyscrasia by a bone marrow biopsy showing predominance of λ - or κ -producing plasma cells or by the presence of a monoclonal light chain in the serum or urine. Immunofixation electrophoresis should be performed on the serum and urine because, in contrast to multiple myeloma, the concentration of the monoclonal light chain often is too low to be detected by simple protein electrophoresis.

The recently introduced serum free-light-chain (FLC) assay, a nephelometric immunoassay, has a sensitivity for circulating free light chains that is reportedly >10-fold that of immunofixation electrophoresis (17,18). Because the FLC assay is quantitative, it has utility not only in diagnosis but also in following disease progression or response to treatment, as is discussed later. The normal concentrations of serum free light chains are 3.3 to 19.4 mg/L for κ isotype and 5.7 to 26.3 mg/L for λ isotype. The normal κ : λ ratio is 0.26 to 1.65 (17,18). Because free light chains undergo glomerular filtration, the ratio, rather than the absolute level, is the relevant measurement in individuals with renal impairment. A κ : λ ratio of <0.26 strongly suggests the presence of a population of plasma cells that are producing clonal λ free light chains, whereas a ratio >1.65 suggests production of clonal κ free light chains.

The diagnostic utility of the FLC is not firmly established but is under evaluation. In a study of 110 patients with a diagnosis of AL amyloidosis, serum immunofixation was positive in 69%, urine immunofixation was positive in 83%, and the κ : λ ratio by the FLC assay was abnormal in 91%. The combination of an abnormal κ : λ ratio and a positive serum immunofixation identified 99% of patients with AL amyloidosis (19). Another study of 169 patients with AL amyloidosis found that an abnormal free κ : λ ratio had greater specificity and predictive value than absolute levels of free light chains in patients with κ clonal disease (20).

Even if a monoclonal Ig light chain is identified in the serum or the urine, a bone marrow biopsy is mandatory to assess the plasma cell burden (21) and exclude multiple myeloma and other, less common disorders that can be associated with AL amyloidosis, such as Waldenström’s macroglobulinemia (22). It is important to recognize that the presence of a monoclonal band on serum immunofixation may be seen as an apparently incidental finding in 5 to 10% of patients who are older than 70 yr (*i.e.*, “monoclonal gammopathy of uncertain significance” [MGUS]) (23). The serum FLC assay often is normal in such cases (24). Because of the high incidence of MGUS in elderly individuals, further testing should be done to exclude familial or senile forms of amyloidosis if the clinical picture is at all atypical for AL disease. Such testing includes immunohistochemistry, immunofluorescence or immunogold electron microscopy of amyloid deposits to identify the amyloidogenic protein (25,26), or genetic testing to rule out familial forms of amyloidosis (27).

Imaging Techniques for Assessment of Organ Involvement

Evaluation of the extent of amyloid deposition is desirable because it can help to prognosticate, formulate therapeutic options, and determine the response to treatment. Currently, physical examination and tissue biopsies are the most widely used methods to determine organ involvement. Scintigraphy using substances that bind to amyloid is a tool that also has utility in identifying affected organs. Technetium Tc 99m pyrophosphate binds avidly to many types of amyloid and has been used to identify cardiac amyloid (28). However, quantitative assessment is not possible with this agent, and strongly positive scintigraphic images usually occur only in patients with severe disease, in whom echocardiography generally is diagnostic. Preliminary results suggest that technetium-labeled aprotinin may be more sensitive for imaging amyloid deposits than technetium Tc 99m pyrophosphate (8). Quantitative scintigraphy also can be performed with ¹²³I-labeled SAP (8) component, a molecule that binds to all types of amyloid (29). Multiple studies have suggested that both disease progression and response to treatment correlate with the degree of uptake of the SAP component, but this test currently is not widely available (29).

The echocardiographic features of cardiac amyloidosis have been well-described and are reasonably distinctive in advanced disease (12). Early experience suggests that magnetic resonance imaging (MRI) may provide an additional method for evaluation of cardiac involvement in amyloidosis and may be particularly useful in distinguishing ventricular wall thickening as a result of amyloid infiltration from ventricular hypertrophy caused by hypertension (30,31). Several investigators have demonstrated abnormal delayed contrast enhancement and abnormal gadolinium distribution kinetics in patients with amyloid cardiomyopathy as compared with hypertensive control subjects (30,31). It has been postulated that the delayed enhancement results from an increase in myocardial interstitial space because of amyloid infiltration. In addition to the delayed enhancement, work using the inherent advantage of cardiac MRI as a three-dimensional imaging technique has suggested that the ratio of left ventricular mass to left ventricular end-diastolic volume might be useful in differentiating cardiac amyloidosis from normal and hypertensive controls (Ruberg *et al.*, unpublished data, 2005), particularly at an early stage of disease. Given these promising findings, cardiac MRI soon may play an important role in both the identification of amyloid cardiomyopathy and the assessment of patients after therapy. The utility of MRI in evaluating amyloid in other organs is not known.

Biomarkers of Prognosis and Treatment Response

The rate of disease progression is variable in AL amyloidosis and depends on the extent of organ involvement. The presence of clinically apparent cardiac involvement is an important determinant of outcome. The serum concentration of N-terminal pro-brain natriuretic peptide, either alone (32) or in conjunction

with levels of cardiac troponins (33), has been shown to be a sensitive marker of AL amyloidosis-associated cardiac dysfunction and a strong predictor of survival after aggressive treatment. High circulating levels of free light chains were shown recently to be associated with poor outcome (34), and greater reductions in levels after treatment of the underlying plasma cell dyscrasia are associated with both reduction in N-terminal pro-brain natriuretic peptide and improved survival (35).

Treatment

The current therapeutic approach to systemic amyloidosis is based on the observations that organ dysfunction improves and survival increases if the synthesis of the amyloidogenic protein precursor is halted. Therefore, the aim of therapy in AL amyloidosis is to reduce rapidly the supply of amyloidogenic monoclonal light chains by suppressing the underlying plasma cell dyscrasia. Decisions about specific treatment regimens for individual patients must take into consideration the balance between anticipated treatment efficacy and tolerability.

Supportive Therapy

Regardless of the specific treatment directed against the plasma cell dyscrasia, supportive care to decrease symptoms and support organ function plays an important role in the management of this disease and requires the coordinated care by specialists in multiple disciplines. The mainstay of the treatment of amyloid cardiomyopathy is sodium restriction and the careful administration of diuretics. Achieving a balance between heart failure and intravascular volume depletion is particularly important, especially in patients with autonomic nervous system involvement or nephrotic syndrome. Diuretic resistance is common in patients with severe nephrotic syndrome, and metolazone or spironolactone may be required in conjunction with loop diuretics. Patients with reduced stroke volume can benefit from afterload reduction with angiotensin-converting enzyme (12) inhibitors. However, these agents should be used cautiously, starting with a low dosage and withdrawing if postural hypotension develops. Digoxin generally is not helpful, with the possible exception in patients with atrial fibrillation and rapid ventricular response. Calcium channel blockers can aggravate congestive heart failure in amyloid cardiomyopathy and generally should be avoided. Patients with recurrent syncope may require permanent pacemaker implantation, and ventricular arrhythmias usually are treated with amiodarone and, in some patients, implantable defibrillators.

Orthostatic hypotension can be severe and difficult to manage. Fitted waist-high elastic stockings and midodrine are helpful. Fludrocortisone often is not a good option because of associated fluid retention. Continuous norepinephrine infusion has been reported to be a successful treatment of severe hypotension that is refractory to conventional treatment. Supportive treatment for amyloid-associated kidney disease, as for other causes of nephrotic syndrome, includes salt restriction, diuretics, and treatment of hyperlipidemia. An impact on proteinuria of angiotensin-converting enzyme inhibitors or angiotensin re-

ceptor blockers has not been established, but it is reasonable to use these agents if not precluded by hypotension. Both hemodialysis and peritoneal dialysis are used for amyloidosis-associated ESRD. Hemodynamic fragility and gastrointestinal symptoms such as early satiety should be considered in modality selection. Diarrhea is a common and incapacitating problem for patients with autonomic nervous system involvement. Octreotide decreases diarrhea in many patients, but chronic intestinal pseudo-obstruction usually is refractory to treatment. Adequate oral or intravenous feeding is mandatory in patients who are undernourished. Neuropathic pain is difficult to control. Gabapentin, although well tolerated, often fails to relieve pain. Other analgesics may be used as adjuvant agents. Bleeding in AL amyloidosis is frequent and multifactorial.

Assessment of Treatment Response

Criteria for hematologic and organ responses for AL amyloidosis were unified and formalized in a recent consensus report (36). Complete hematologic response (CR) is defined as absence of monoclonal protein in serum and urine by immunofixation electrophoresis, normal serum free light chain ratio, and bone marrow biopsy with <5% plasma cells with no clonal predominance by immunohistochemistry. All of these parameters must be present to classify the response as a CR. Hematologic response is associated with a substantial survival advantage, improved quality of life, and improved organ function (3,37). Improved organ function may be evident 3 to 6 mo after treatment, although more delayed responses also occur. Reduction in proteinuria is gradual with continued improvement over 2 or more years. Importantly, a complete clonal hematologic response (CR) is not a prerequisite for clinical response, and clinical improvement still may occur in patients with a partial clonal response (3). However, the rate of clinical re-

sponse is higher in patients with a CR than in those with a partial one. In one report, a reduction in FLC of >90% was associated with a similar high likelihood of clinical improvement and prolonged survival, regardless of whether patients achieved a CR after treatment (38).

High-Dose Melphalan and Autologous Peripheral Blood Stem Cell Transplantation

High-dose melphalan (HDM) followed by autologous peripheral blood stem cell transplantation (SCT) presently is considered the most effective treatment for AL amyloidosis (3,4,39). The results of single-center and multicenter studies of HDM/SCT are summarized in Table 1 (3,40–50). Encouraging hematologic and clinical responses have been reported in these studies, and although these are not controlled trials, the rates of CR (25 to 67%) far exceed those that are observed with cyclic oral melphalan and prednisone, treatment that had been standard until the past several years.

The major limitation of HDM/SCT is its toxicity. Treatment-related mortality is substantially higher with HDM/SCT for AL amyloidosis (15 to 40%) than for multiple myeloma (<5%), undoubtedly because of the underlying organ dysfunction that is present in the former. Advanced cardiac disease, reduced renal function, involvement of more than two organs, severe hypotension, and poor performance status are predictors of high treatment-associated morbidity and mortality.

Eligibility Criteria for HDM/SCT. The eligibility criteria for HDM/SCT in AL amyloidosis vary among institutions and have evolved as experience has accrued, but all aim to make the treatment available to as many patients as possible while excluding those who are at greatest risk for severe morbidity and mortality. The Boston University Amyloid Program eligibility criteria include a confirmed tissue diagnosis of amyloidosis,

Table 1. Results of single-center and multicenter studies of HDM/SCT in AL amyloidosis^a

Parameter	No. of Patients	Melphalan Dosage (mg/m ²)	TRM (%)	CR (%)	Organ Response (%)	Survival
Single-center experience						
Reich <i>et al.</i> , 2001 (40)	4	140 to 200	50	25	50	50% at 1 yr
Van Gamen <i>et al.</i> , 2002 (41)	11	NA	NA	0	67	75% at 2 yr
Blum <i>et al.</i> , 2003 (42)	12	ND	15	27	NA	NA
Gertz <i>et al.</i> , 2004 (47)	171	100 to 200	12	77 ^b	NA	NA
Mollee <i>et al.</i> , 2004 (44)	20	140 to 200	35	45	NA	56% at 3 yr
Perz <i>et al.</i> , 2004 (45)	24	100 to 200	13	52	NA	84% at 2 yr
Skinner <i>et al.</i> , 2004 (3)	277	100 to 200	13	40	44	47% at 5 yr
Chow <i>et al.</i> , 2005 (46)	15	170 to 200	0	67	27	75% at 4 yr
Multicenter experience						
Moreau <i>et al.</i> , 1998 (48)	21	140 to 200	43	25	83	57% at 4 yr
Vesole <i>et al.</i> , 2006 (49)	107	140 to 200	18	36		56% at 3 yr
Gertz <i>et al.</i> , 2004 (43)	28	200	14	NA	75	62% at 3 yr
Goodman <i>et al.</i> , 2006 (50)	92	140 to 200	23	83 ^b	NA	5.3 yr

^aCR, complete hematologic response; HDM/SCT, high-dose melphalan and stem cell transplantation; NA, not applicable; ND, not determined; TRM, treatment-related mortality.

^bIncludes partial and complete hemotologic responses.

clear evidence of a clonal plasma cell dyscrasia, age >18 yr, performance status of 0 to 2 using the Southwest Oncology Group criteria, left ventricular ejection fraction >40%, room air oxygen saturation >95%, and supine systolic BP >90 mmHg. Renal impairment including dialysis dependence is not an exclusion criterion. The dosage of melphalan can vary from 100 to 200 mg/m² depending on anticipated tolerability, using risk-adapted approaches such as that described by Comenzo and Gertz (51).

Stem Cell Mobilization and Collection. Several aspects of stem cell mobilization and collection pose particular challenges in patients with AL amyloidosis. As with other diseases, previous exposure to alkylating agents impairs hematopoietic stem cell collection; for melphalan, a previous cumulative dosage exceeding 200 mg significantly reduces the ability to mobilize stem cells. This is an important consideration if oral melphalan therapy is used before embarking on HDM/SCT or if a second course of HDM is a possibility in the event of an incomplete hematologic response with the initial course. Patients with AL amyloidosis have more difficulty tolerating the stem cell mobilization and collection processes than do patients with other underlying diseases. Contrary to the typical experience in multiple myeloma, deaths have been reported during mobilization and leukapheresis in AL amyloidosis patients with cardiac or multiorgan involvement (3). Overall, the major complication rate during mobilization or collection is approximately 15% in this disease (3).

To minimize the risk for toxicity, it is recommended that granulocyte colony-stimulating factor be used as a sole mobilizing agent because its use in combination with cyclophosphamide is associated with increased cardiac morbidity, the need for a greater number of apheresis sessions to obtain adequate numbers of stem cells, greater need of hospitalization, and increased toxicity overall (47). Contamination of the apheresis product with clonotypic Ig-positive plasma cells has been demonstrated, but CD34 selection presently is not recommended (52).

Induction and Conditioning Chemotherapy Regimen before SCT. Because the burden of clonal plasma cells is modest in most patients with AL amyloidosis, induction with a cytoreducing regimen before HDM/SCT, as is done in multiple myeloma, seems unnecessary, although possible benefits from vincristine, Adriamycin, and dexamethasone (VAD) treatment before SCT have been claimed (53). Evidence from a randomized trial indicates that the delay that is associated with pretransplantation cytoreduction using two cycles of oral melphalan and prednisone is likely to allow disease progression (54). Total body irradiation (550 cGy) before SCT was investigated in a small feasibility study but is not used in current regimens because of cardiac toxicity and what seems to be greater overall morbidity and mortality. Tandem cycles of HDM in which adequate stem cells for two courses of chemotherapy are collected before the initial course of treatment currently is being explored in a clinical trial.

Hematologic and Clinical Responses to HDM/SCT. The details of the hematologic clonal responses and organ responses are tabulated in Table 1. The initial report of renal

response after HDM/SCT was published in 2001 (55). In this report, 36% of patients had a renal response at 12 months defined as a 50% reduction in 24-h urinary protein excretion in the absence of a 25% or greater reduction in creatinine clearance. There was a striking difference in renal response rate among those with a CR (71%) and those with persistence of the plasma cell dyscrasia (11%) (55).

Special Problems Associated with HDM/SCT in AL Amyloidosis. Several challenges with HDM/SCT are unique to patients with AL amyloidosis. Amyloid deposition in the gastrointestinal tract predisposes to gastrointestinal bleeding during periods of cytopenia; this can be exacerbated by amyloid-associated coagulopathies such as factor X deficiency. Anasarca is common in patients with nephrotic syndrome, particularly in association with granulocyte colony-stimulating factor administration. Hypotension from cardiac disease or autonomic nervous system involvement, atrial and ventricular arrhythmias in patients with amyloid cardiomyopathy, difficulties with emergent endotracheal intubation as a result of macroglossia, and spontaneous splenic and esophageal rupture also are problems that can arise during treatment in these patients.

HDM/SCT after Heart Transplantation. In patients with end-stage heart failure, heart transplantation may be required as a life-saving procedure. Because of the high likelihood of amyloid recurrence in the transplanted organ, as well as progression in other organs, heart transplantation must be followed by anticlonal therapy (56). Although the long-term survival is statistically inferior to that of patients with nonamyloid heart disease, the actuarial 5-yr survival seems to be 50% with treatment for the underlying plasma cell dyscrasia. Therefore, carefully selected patients, without other significant organ involvement, can benefit from heart transplantation followed by aggressive anti-plasma cell treatment.

Allogeneic Bone Marrow Transplantation

There is a small experience with allogeneic and syngeneic bone marrow transplantation for AL amyloidosis. A recent report by the European Cooperative Group for Blood and Marrow Transplantation described 19 patients who underwent allogeneic transplantation (57). The group is heterogeneous because it included four syngeneic, eight reduced-intensity conditioning, and seven full-dose allogeneic transplants, and 10 were T cell-depleted grafts. CR were seen in 10 of the 19 patients. However, the follow-up period was short, the treatment-related mortality was 40%, and only four patients were alive at 36 mo. This report was compiled from registry data from 11 centers. The patient selection and the total number of patients who were evaluated at these centers as potential allogeneic transplant recipients are not known. Nonetheless, it represents the largest number of patients reported, and it is important for the scientific community to be aware of the feasibility of allogeneic transplant and its potential for graft *versus* tumor, because five of seven patients with complete remission had chronic graft-*versus*-host disease. The data are of insufficient power to justify the use of this technique in clinical practice, and it should remain the subject of clinical trials.

Conventional Treatment: Oral Melphalan–Based Regimens

The conventional treatment approach for AL amyloidosis, adopted from experience with multiple myeloma, is to administer low-dose oral melphalan in association with prednisone in a cyclical manner. Two randomized, clinical trials demonstrated the efficacy of this regimen; however, the impact was modest, increasing the median patients survival to only approximately 18 mo. This form of treatment only rarely results in CR or reversal of amyloid-related organ dysfunction (58,59).

Many patients with advanced disease, particularly those with cardiac involvement, are unable to tolerate the fluid retention and worsening congestive heart failure that are associated with steroid treatment. The use of sole therapy with oral melphalan administered continuously rather than cyclically has been studied in patients with cardiac amyloidosis. In 30 such treated patients, seven of 13 patients who were assessable after 3 to 4 months of treatment achieved a partial hematologic response and three achieved a CR. Six of the patients survived for >1 yr. This regimen seemed to be effective in inducing hematologic responses in patients who received total dosages of melphalan of >300 mg (60).

High-Dose Dexamethasone–Based Regimens

A rapid response to therapy is essential in AL amyloidosis. In multiple myeloma, VAD may induce a quick clonal response. However, this regimen presents potential problems in patients with AL amyloidosis: Vincristine can exacerbate autonomic or peripheral neuropathy; doxorubicin can worsen cardiomyopathy; and the intensive high-dosage dexamethasone can cause severe fluid retention in patients with renal and cardiac amyloidosis or trigger severe, often fatal, ventricular arrhythmias. At the UK National Amyloidosis Center, 98 patients with AL amyloidosis were treated with a median of four cycles of standard VAD or cyclophosphamide, vincristine, Adriamycin, and methylprednisolone. A hematologic response occurred in 54%, an organ response was evident in 42%, and the treatment-related mortality was only 7%. However, the responses were not durable with evidence of hematologic relapse in 21% of patients after a median time of 20 mo (range 7 to 54).

Experience with multiple myeloma has indicated that dexamethasone accounted for most (80%) of the plasma cell reduction achieved with VAD and avoided the potential toxicity of vincristine and Adriamycin. Pulsed high-dosage dexamethasone, as used in the VAD regimen, has been reported to benefit AL patients with varying response rates. A recently completed Southwest Oncology Group trial with 87 eligible and analyzable patients found that 53% of patients had a hematologic response, and the hematologic response was complete in 24%. Organ function improved in 45%. The median progression-free survival was 27 mo, and overall survival was 31 mo (61).

The toxicity of dexamethasone used with the same schedule of the VAD regimen in AL patients is substantial. A modified-dexamethasone, milder, less toxic schedule (40 mg/d for 4 d every 21 d) induced organ response in 35% of patients in a median time of 4 mo, without significant toxicity (62). The combination of melphalan and dexamethasone produced hematologic response in 67% in a median time of 4.5 mo, with

complete remission in 33% and functional improvement of the involved organs in 48%. Treatment-related mortality was low (4%). Median duration of response was 24 mo (range 12 to 48) (63).

Thalidomide

Thalidomide is poorly tolerated in patients with AL amyloidosis, causing fatigue, progressive edema, cognitive difficulties, constipation, neuropathy, syncope as a result of bradycardia, thromboembolic complications, and worsening of renal function. Severe adverse effects impeded dosage escalation above 200 to 300 mg/d and necessitated thalidomide withdrawal in 25 to 50% of the patients (64,65). Thalidomide was given in combination with intermediate-dosage dexamethasone in 31 patients with AL amyloidosis as a second-line therapy. Hematologic and organ responses correlated with the dosage of thalidomide. Overall hematologic response was observed in 15 (48%) patients, 6 (19%) of whom attained a complete response and 8 (26%) of whom attained organ response. Median time to response was 3.6 mo (range 2.5 to 8.0 mo). Hematologic response to treatment resulted in a significant survival benefit ($P = 0.01$). Treatment-related toxicity was frequent (65%), and symptomatic bradycardia was a common (26%) adverse reaction (66). Similar results are reported by other investigators with respect to tolerability and efficacy of thalidomide alone or in combination.

Overall, it seems that the combination of thalidomide and dexamethasone may be a valid option for refractory or relapsed patients. Because of the fragility of these patients, reduced dosages of thalidomide should be used, and careful monitoring for toxicity is necessary.

Investigational Therapies

The thalidomide analog lenalidomide and the proteasome inhibitor bortezomib both are active in multiple myeloma (67–70). The ability of these drugs, in combination with dexamethasone, to reduce rapidly the concentration of the circulating monoclonal protein in multiple myeloma makes them attractive options also for AL amyloidosis, although more data on response duration and toxicity are needed. In small studies of patients who had AL amyloidosis and either had persistent disease after HDM/SCT or were ineligible for HDM/SCT, lenalidomide with dexamethasone has been found to produce hematologic response in 60% of patients with considerable organ responses (71); however, these clinical trials still are under way. Lenalidomide has a different toxicity profile than thalidomide. Adverse events of thromboembolic complications, myelosuppression, and immunosuppression are noted with lenalidomide, and neurotoxicity generally is not associated with lenalidomide.

An iodinated derivative of doxorubicin, 4-iodo-4-deoxydoxorubicin (IDOX), binds with high affinity to amyloid fibrils and promotes their disaggregation *in vitro* and *in vivo* in experimentally induced murine AA amyloidosis (72–74). Administration of IDOX to patients with AL amyloidosis showed promising results in a small, uncontrolled series, but its efficacy was unable to be demonstrated in a larger, multicenter trial, possi-

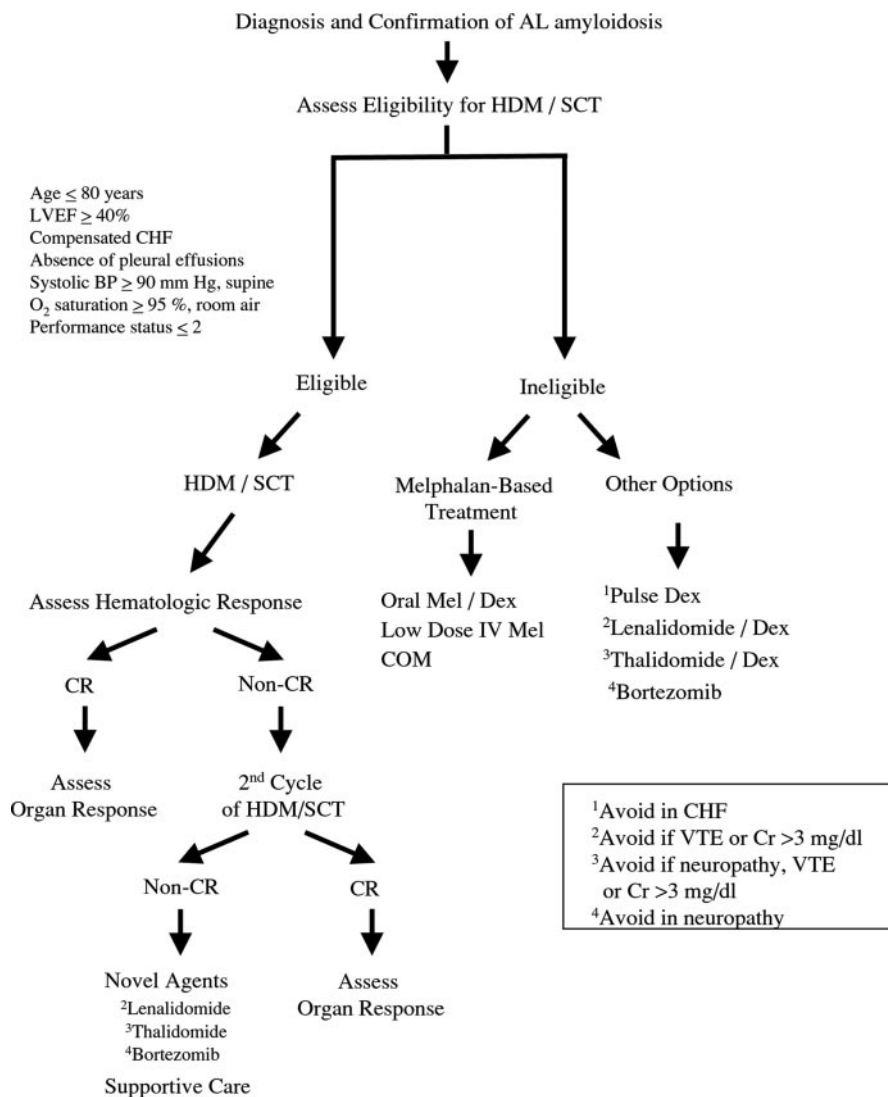


Figure 1. Treatment algorithm for light-chain (AL) amyloidosis. CHF, congestive heart failure; COM, continuous low-dosage oral melphalan; CR, complete hematologic response; Cr, creatinine; Dex, dexamethasone; HDM/SCT, high-dosage melphalan and stem cell transplantation; IV, intravenous; LVEF, left ventricular ejection fraction; Mel, melphalan; VTE, venous thromboembolic disease.

bly because the effect size was less than anticipated (75,76). Strategies that combine IDOX with chemotherapy to suppress precursor production and promote amyloid resorption is a rational approach that warrants investigation.

Disruption of the interaction between SAP (7) and amyloid is another approach being investigated as a degradation-promoting treatment. Because SAP is present in all types of amyloid deposits, targeting the SAP-amyloid interaction could have broad application (77). SAP itself is highly resistant to proteolysis, and binding of SAP to amyloid fibrils protects them from proteolysis *in vitro* (78). SAP exists in a dynamic equilibrium between the circulation, where it is unbound, and tissue, where it is bound to amyloid. Pepys *et al.* (79) hypothesized that removal of circulating SAP would drive SAP from tissue amyloid to the circulation and render the tissue amyloid less resistant to proteolysis. R-1-[6-[R-2-carboxy-pyrrolidin-1-yl]-6-oxo-hexanoyl]pyrrolidine-2-carboxylic acid (CPHPC), a palindromic

compound that binds with high affinity to SAP, cross-links two SAP molecules together in a manner that occludes the binding surface of SAP. CPHPC administration depleted SAP from the circulation and from amyloid deposits in murine models, and studies in humans demonstrated rapid SAP clearance from the circulation (79). However, the impact of CPHPC administration on amyloid deposits in either animal models or humans is not known and currently is being studied in phase II trials.

Anti-TNF- α therapy, in the form of etanercept, in 16 patients with advanced AL amyloidosis produced symptomatic improvement in most of them, and half had objective responses, notably in those with macroglossia (80). However, this approach does not have any impact on the underlying plasma cell dyscrasia and therefore is of limited benefit.

Immunotherapy, both active and passive, is another approach that is being pursued actively. Dendritic cell-based idiotype vaccination has been shown to be well tolerated but to

have limited clinical impact. AL amyloid burden can be reduced markedly in mice by passive immunization with an anti-light-chain murine mAb that is specific for an amyloid-related epitope (81). A humanized antibody is being produced for a phase I/II clinical trial in patients with AL disease.

Treatment Algorithm

A summary of my recommendations for the treatment of AL amyloidosis is outlined in Figure 1.

Conclusions

Promising treatments are available for patients with AL amyloidosis. Prompt diagnosis of amyloidosis and appropriate referral have the potential to improve outcome for these patients. Maintaining AL amyloidosis in the differential diagnosis of patients who are being evaluated for a variety of syndromes, particularly with nephrotic-range proteinuria, unexplained nonischemic cardiomyopathy, peripheral neuropathy, unexplained hepatomegaly, or atypical multiple myeloma should improve diagnostic efficiency. Despite these improvements in the treatment and diagnosis of AL amyloidosis, continued basic and clinical research effort in this field is needed to help improve the outcome for these patients.

References

1. Westermark P, Benson MD, Buxbaum JN, Cohen AS, Frangione B, Ikeda S, Masters CL, Merlini G, Saraiva MJ, Sipe JD: Amyloid fibril protein nomenclature—2002. *Amyloid* 9: 197–200, 2002
2. Gertz MA LM, Dispenzieri A: Amyloidosis. *Hematol Oncol Clin North Am* 13:1211–1220, 1999
3. Skinner M, Sancharawala V, Seldin DC, Dember LM, Falk RH, Berk JL, Anderson JJ, O'Hara C, Finn KT, Libbey CA, Wiesman J, Quillen K, Swan N, Wright DG: High-dose melphalan and autologous stem-cell transplantation in patients with AL amyloidosis: An 8-year study. *Ann Intern Med* 140: 85–93, 2004
4. Sancharawala V, Wright DG, Seldin DC, Dember LM, Finn K, Falk RH, Berk J, Quillen K, Skinner M: An overview of the use of high-dose melphalan with autologous stem cell transplantation for the treatment of AL amyloidosis. *Bone Marrow Transplant* 28: 637–642, 2001
5. Kyle RA GM: Primary systemic amyloidosis: Clinical and laboratory features in 474 cases. *Semin Hematol* 32: 45–49, 1995
6. Merlini G, Bellotti V: Molecular mechanisms of amyloidosis. *N Engl J Med* 349: 583–596, 2003
7. Kisilevsky R: The relation of proteoglycans, serum amyloid P and apo E to amyloidosis current status, 2000. *Amyloid* 7: 23–25, 2000
8. Aprile C, Marinone G, Saponaro R, Bonino C, Merlini G: Cardiac and pleuropulmonary AL amyloid imaging with technetium-99m labelled aprotinin. *Eur J Nucl Med* 22: 1393–1401, 1995
9. Brenner DA, Jain M, Pimentel DR, Wang B, Connors LH, Skinner M, Apstein CS, Liao R: Human amyloidogenic light chains directly impair cardiomyocyte function through an increase in cellular oxidant stress. *Circ Res* 94: 1008–1010, 2004
10. Abraham RS, Ballman KV, Dispenzieri A, Grill DE, Manske MK, Price-Troska TL, Paz NG, Gertz MA, Fonseca R: Functional gene expression analysis of clonal plasma cells identifies a unique molecular profile for light chain amyloidosis. *Blood* 105: 794–803, 2005
11. Comenzo RL, Zhang Y, Martinez C, Osman K, Herrera GA: The tropism of organ involvement in primary systemic amyloidosis: Contributions of Ig V(L) germ line gene use and clonal plasma cell burden. *Blood* 98: 714–720, 2001
12. Falk RH: Diagnosis and management of the cardiac amyloidoses. *Circulation* 112: 2047–2060, 2005
13. Dember LM: Emerging treatment approaches for the systemic amyloidoses. *Kidney Int* 68: 1377–1390, 2005
14. Park MA, Mueller PS, Kyle RA, Larson DR, Plevak MF, Gertz MA: Primary (AL) hepatic amyloidosis: Clinical features and natural history in 98 patients. *Medicine (Baltimore)* 82: 291–298, 2003
15. Libbey CA, Skinner M, Cohen AS: Use of abdominal fat tissue aspirate in the diagnosis of systemic amyloidosis. *Arch Intern Med* 143: 1549–1552, 1983
16. Ansari-Lari MA, Ali SZ: Fine-needle aspiration of abdominal fat pad for amyloid detection: A clinically useful test? *Diagn Cytopathol* 30: 178–181, 2004
17. Abraham RS, Katzmman JA, Clark RJ, Bradwell AR, Kyle RA, Gertz MA: Quantitative analysis of serum free light chains. A new marker for the diagnostic evaluation of primary systemic amyloidosis. *Am J Clin Pathol* 119: 274–278, 2003
18. Katzmman JA, Clark RJ, Abraham RS, Bryant S, Lymp JF, Bradwell AR, Kyle RA: Serum reference intervals and diagnostic ranges for free kappa and free lambda immunoglobulin light chains: Relative sensitivity for detection of monoclonal light chains. *Clin Chem* 48: 1437–1444, 2002
19. Katzmman JA, Abraham RS, Dispenzieri A, Lust JA, Kyle RA: Diagnostic performance of quantitative kappa and lambda free light chain assays in clinical practice. *Clin Chem* 51: 878–881, 2005
20. Akar H, Seldin DC, Magnani B, O'Hara C, Berk JL, Schoonmaker C, Cabral H, Dember LM, Sancharawala V, Connors LH, Falk RH, Skinner M: Quantitative serum free light chain assay in the diagnostic evaluation of AL amyloidosis. *Amyloid* 12: 210–215, 2005
21. Swan N, Skinner M, O'Hara CJ: Bone marrow core biopsy specimens in AL (primary) amyloidosis. A morphologic and immunohistochemical study of 100 cases. *Am J Clin Pathol* 120: 610–616, 2003
22. Sancharawala V, Blanchard E, Seldin DC, O'Hara C, Skinner M, Wright DG: AL amyloidosis associated with B-cell lymphoproliferative disorders: Frequency and treatment outcomes. *Am J Hematol* 81: 692–695, 2006
23. Kyle RA, Therneau TM, Rajkumar SV, Larson DR, Plevak MF, Melton LJ 3rd: Long-term follow-up of 241 patients with monoclonal gammopathy of undetermined significance: The original Mayo Clinic series 25 years later. *Mayo Clin Proc* 79: 859–866, 2004
24. Rajkumar SV, Kyle RA, Therneau TM, Clark RJ, Bradwell AR, Melton LJ 3rd, Larson DR, Plevak MF, Katzmman JA: Presence of monoclonal free light chains in the serum predicts risk of progression in monoclonal gammopathy of undetermined significance. *Br J Haematol* 127: 308–310, 2004
25. Arbustini E, Verga L, Concardi M, Palladini G, Obici L, Merlini G: Electron and immuno-electron microscopy of

- abdominal fat identifies and characterizes amyloid fibrils in suspected cardiac amyloidosis. *Amyloid* 9: 108–114, 2002
26. O'Hara CJ, Falk RH: The diagnosis and typing of cardiac amyloidosis. *Amyloid* 10: 127–129, 2003
 27. Lachmann HJ, Booth DR, Booth SE, Bybee A, Gilbertson JA, Gillmore JD, Pepys MB, Hawkins PN: Misdiagnosis of hereditary amyloidosis as AL (primary) amyloidosis. *N Engl J Med* 346: 1786–1791, 2002
 28. Falk RH, Lee VW, Rubinow A, Skinner M, Cohen AS: Cardiac technetium-99m pyrophosphate scintigraphy in familial amyloidosis. *Am J Cardiol* 54: 1150–1151, 1984
 29. Hawkins PN, Lavender JP, Pepys MB: Evaluation of systemic amyloidosis by scintigraphy with 123I-labeled serum amyloid P component. *N Engl J Med* 323: 508–513, 1990
 30. Maceira AM, Joshi J, Prasad SK, Moon JC, Perugini E, Harding I, Sheppard MN, Poole-Wilson PA, Hawkins PN, Pennell DJ: Cardiovascular magnetic resonance in cardiac amyloidosis. *Circulation* 111: 186–193, 2005
 31. Perugini E, Rapezzi C, Piva T, Leone O, Bacchi-Reggiani L, Riva L, Salvi F, Lovato L, Branzi A, Fattori R: Non-invasive evaluation of the myocardial substrate of cardiac amyloidosis by gadolinium cardiac magnetic resonance. *Heart* 92: 343–349, 2006
 32. Palladini G, Campana C, Klersy C, Balduini A, Vadacca G, Perfetti V, Perlini S, Obici L, Ascari E, d'Eril GM, Moratti R, Merlini G: Serum N-terminal pro-brain natriuretic peptide is a sensitive marker of myocardial dysfunction in AL amyloidosis. *Circulation* 107: 2440–2445, 2003
 33. Dispenzieri A, Gertz MA, Kyle RA, Lacy MQ, Burritt MF, Therneau TM, McConnell JP, Litzow MR, Gastineau DA, Tefferi A, Inwards DJ, Micallef IN, Ansell SM, Porrata LF, Elliott MA, Hogan WJ, Rajkumar SV, Fonseca R, Greipp PR, Witzig TE, Lust JA, Zeldenrust SR, Snow DS, Hayman SR, McGregor CG, Jaffe AS: Prognostication of survival using cardiac troponins and N-terminal pro-brain natriuretic peptide in patients with primary systemic amyloidosis undergoing peripheral blood stem cell transplantation. *Blood* 104: 1881–1887, 2004
 34. Dispenzieri A, Lacy MQ, Katzmann JA, Rajkumar SV, Abraham RS, Hayman SR, Kumar SK, Clark R, Kyle RA, Litzow MR, Inwards DJ, Ansell SM, Micallef IM, Porrata LF, Elliott MA, Johnston PB, Greipp PR, Witzig TE, Zeldenrust SR, Russell SJ, Gastineau D, Gertz MA: Absolute values of immunoglobulin free light chains are prognostic in patients with primary systemic amyloidosis undergoing peripheral blood stem cell transplant. *Blood* 107: 3378–3383, 2006
 35. Palladini G, Lavatelli F, Russo P, Perlini S, Perfetti V, Bosoni T, Obici L, Bradwell AR, D'Eril GM, Fogari R, Moratti R, Merlini G: Circulating amyloidogenic free light chains and serum N-terminal natriuretic peptide type B decrease simultaneously in association with improvement of survival in AL. *Blood* 107: 3854–3858, 2006
 36. Gertz MA, Comenzo R, Falk RH, Fermand JP, Hazenberg BP, Hawkins PN, Merlini G, Moreau P, Ronco P, Santhorawala V, Sezer O, Solomon A, Grateau G: Definition of organ involvement and treatment response in immunoglobulin light chain amyloidosis (AL): A consensus opinion from the 10th International Symposium on Amyloid and Amyloidosis, Tours, France, 18–22 April 2004. *Am J Hematol* 79: 319–328, 2005
 37. Seldin DC, Anderson JJ, Santhorawala V, Malek K, Wright DG, Quillen K, Finn KT, Berk JL, Dember LM, Falk RH, Skinner M: Improvement in quality of life of patients with AL amyloidosis treated with high-dose melphalan and autologous stem cell transplantation. *Blood* 104: 1888–1893, 2004
 38. Santhorawala V, Seldin DC, Magnani B, Skinner M, Wright DG: Serum free light-chain responses after high-dose intravenous melphalan and autologous stem cell transplantation for AL (primary) amyloidosis. *Bone Marrow Transplant* 36: 597–600, 2005
 39. Dispenzieri A, Kyle RA, Lacy MQ, Therneau TM, Larson DR, Plevak MF, Rajkumar SV, Fonseca R, Greipp PR, Witzig TE, Lust JA, Zeldenrust SR, Snow DS, Hayman SR, Litzow MR, Gastineau DA, Tefferi A, Inwards DJ, Micallef IN, Ansell SM, Porrata LF, Elliott MA, Gertz MA: Superior survival in primary systemic amyloidosis patients undergoing peripheral blood stem cell transplantation: A case-control study. *Blood* 103: 3960–3963, 2004
 40. Reich G, Held T, Siegert W, Kampf D, Dorken B, Maschmeyer G: Four patients with AL amyloidosis treated with high-dose chemotherapy and autologous stem cell transplantation. *Bone Marrow Transplant* 27: 341–343, 2001
 41. van Gameren II, Hazenberg BP, Jager PL, Smit JW, Velenga E: AL amyloidosis treated with induction chemotherapy with VAD followed by high dose melphalan and autologous stem cell transplantation. *Amyloid* 9: 165–174, 2002
 42. Blum W, Khoury H, Lin HS, Vij R, Goodnough LT, Devine S, Dipersio J, Adkins D: Primary amyloidosis patients with significant organ dysfunction tolerate autologous transplantation after conditioning with single-dose total body irradiation alone: A feasibility study. *Biol Blood Marrow Transplant* 9: 397–404, 2003
 43. Gertz MA, Blood E, Vesole DH, Abonour R, Lazarus HM, Greipp PR: A multicenter phase 2 trial of stem cell transplantation for immunoglobulin light-chain amyloidosis (E4A97): An Eastern Cooperative Oncology Group Study. *Bone Marrow Transplant* 34: 149–154, 2004
 44. Mollee PN, Wechalekar AD, Pereira DL, Franke N, Reece D, Chen C, Stewart AK: Autologous stem cell transplantation in primary systemic amyloidosis: The impact of selection criteria on outcome. *Bone Marrow Transplant* 33: 271–277, 2004
 45. Perz JB, Schonland SO, Hundemer M, Kristen AV, Dengler TJ, Zeier M, Linke RP, Ho AD, Goldschmidt H: High-dose melphalan with autologous stem cell transplantation after VAD induction chemotherapy for treatment of amyloid light chain amyloidosis: A single centre prospective phase II study. *Br J Haematol* 127: 543–551, 2004
 46. Chow LQ, Bahlis N, Russell J, Chaudhry A, Morris D, Brown C, Stewart DA: Autologous transplantation for primary systemic AL amyloidosis is feasible outside a major amyloidosis referral centre: The Calgary BMT Program experience. *Bone Marrow Transplant* 36: 591–596, 2005
 47. Gertz MA, Lacy MQ, Dispenzieri A, Ansell SM, Elliott MA, Gastineau DA, Inwards DJ, Micallef IN, Porrata LF, Tefferi A, Litzow MR: Risk-adjusted manipulation of melphalan dose before stem cell transplantation in patients with amyloidosis is associated with a lower response rate. *Bone Marrow Transplant* 34: 1025–1031, 2004
 48. Moreau P, Leblond V, Bourquelot P, Facon T, Huynh A, Caillot D, Hermine O, Attal M, Hamidou M, Nedellec G,

- Ferrant A, Audhuy B, Bataille R, Milpied N, Harousseau JL: Prognostic factors for survival and response after high-dose therapy and autologous stem cell transplantation in systemic AL amyloidosis: A report on 21 patients. *Br J Haematol* 101: 766-769, 1998
49. Vesole DH, Perez WS, Akasheh M, Boudreau C, Reece DE, Bredeson CN: High-dose therapy and autologous hematopoietic stem cell transplantation for patients with primary systemic amyloidosis: A Center for International Blood and Marrow Transplant Research Study. *Mayo Clin Proc* 81: 880-888, 2006
50. Goodman HJ, Gillmore JD, Lachmann HJ, Wechalekar AD, Bradwell AR, Hawkins PN: Outcome of autologous stem cell transplantation for AL amyloidosis in the UK. *Br J Haematol* 134: 417-425, 2006
51. Comenzo RL, Gertz MA: Autologous stem cell transplantation for primary systemic amyloidosis. *Blood* 99: 4276-4282, 2002
52. Comenzo RL, Michelle D, LeBlanc M, Wally J, Zhang Y, Kica G, Karandish S, Arkin CF, Wright DG, Skinner M, McMannis J: Mobilized CD34+ cells selected as autografts in patients with primary light-chain amyloidosis: Rationale and application. *Transfusion* 38: 60-69, 1998
53. Attal M, Harousseau JL, Stoppa AM, Sotto JJ, Fuzibet JG, Rossi JF, Casassus P, Maisonneuve H, Facon T, Ifrah N, Payen C, Bataille R: A prospective, randomized trial of autologous bone marrow transplantation and chemotherapy in multiple myeloma. Intergroupe Francais du Myelome. *N Engl J Med* 335: 91-97, 1996
54. Sancharawala V, Wright DG, Seldin DC, Falk RH, Finn KT, Dember LM, Berk JL, Quillen K, Anderson JJ, Comenzo RL, Skinner M: High-dose intravenous melphalan and autologous stem cell transplantation as initial therapy or following two cycles of oral chemotherapy for the treatment of AL amyloidosis: Results of a prospective randomized trial. *Bone Marrow Transplant* 33: 381-388, 2004
55. Dember LM, Sancharawala V, Seldin DC, Wright DG, LaValley M, Berk JL, Falk RH, Skinner M: Effect of dose-intensive intravenous melphalan and autologous blood stem-cell transplantation on AL amyloidosis-associated renal disease. *Ann Intern Med* 134: 746-753, 2001
56. Gillmore JD, Goodman HJ, Lachmann HJ, Offer M, Wechalekar AD, Joshi J, Pepys MB, Hawkins PN: Sequential heart and autologous stem cell transplantation for systemic AL amyloidosis. *Blood* 107: 1227-1229, 2006
57. Schonland SO, Lokhorst H, Buzyn A, Leblond V, Hegenbart U, Bandini G, Campbell A, Carreras E, Ferrant A, Grommisch L, Jacobs P, Kroger N, La Nasa G, Russell N, Zachee P, Goldschmidt H, Iacobelli S, Niederwieser D, Gahrton G: Allogeneic and syngeneic hematopoietic cell transplantation in patients with amyloid light-chain amyloidosis: A report from the European Group for Blood and Marrow Transplantation. *Blood* 107: 2578-2584, 2006
58. Skinner M, Anderson J, Simms R, Falk R, Wang M, Libbey C, Jones LA, Cohen AS: Treatment of 100 patients with primary amyloidosis: A randomized trial of melphalan, prednisone, and colchicine versus colchicine only. *Am J Med* 100: 290-298, 1996
59. Kyle RA, Gertz MA, Greipp PR, Witzig TE, Lust JA, Lacy MQ, Therneau TM: A trial of three regimens for primary amyloidosis: Colchicine alone, melphalan and prednisone, and melphalan, prednisone, and colchicine. *N Engl J Med* 336: 1202-1207, 1997
60. Sancharawala V, Wright DG, Seldin DC, Falk RH, Berk JL, Dember LM, Finn KT, Skinner M: Low-dose continuous oral melphalan for the treatment of primary systemic (AL) amyloidosis. *Br J Haematol* 117: 886-889, 2002
61. Dhodapkar MV, Hussein MA, Rasmussen E, Solomon A, Larson RA, Crowley JJ, Barlogie B: Clinical efficacy of high-dose dexamethasone with maintenance dexamethasone/alpha interferon in patients with primary systemic amyloidosis: Results of United States Intergroup Trial Southwest Oncology Group (SWOG) S9628. *Blood* 104: 3520-3526, 2004
62. Palladini G, Anesi E, Perfetti V, Obici L, Invernizzi R, Balduini C, Ascari E, Merlini G: A modified high-dose dexamethasone regimen for primary systemic (AL) amyloidosis. *Br J Haematol* 113: 1044-1046, 2001
63. Palladini G, Perfetti V, Obici L, Caccialanza R, Semino A, Adami F, Cavallero G, Rustichelli R, Virga G, Merlini G: Association of melphalan and high-dose dexamethasone is effective and well tolerated in patients with AL (primary) amyloidosis who are ineligible for stem cell transplantation. *Blood* 103: 2936-2938, 2004
64. Seldin DC, Choufani EB, Dember LM, Wiesman JF, Berk JL, Falk RH, O'Hara C, Fennessey S, Finn KT, Wright DG, Skinner M, Sancharawala V: Tolerability and efficacy of thalidomide for the treatment of patients with light chain-associated (AL) amyloidosis. *Clin Lymphoma* 3: 241-246, 2003
65. Dispenzieri A, Lacy MQ, Rajkumar SV, Geyer SM, Witzig TE, Fonseca R, Lust JA, Greipp PR, Kyle RA, Gertz MA: Poor tolerance to high doses of thalidomide in patients with primary systemic amyloidosis. *Amyloid* 10: 257-261, 2003
66. Palladini G, Perfetti V, Perlini S, Obici L, Lavatelli F, Caccialanza R, Invernizzi R, Comotti B, Merlini G: The combination of thalidomide and intermediate-dose dexamethasone is an effective but toxic treatment for patients with primary amyloidosis (AL). *Blood* 105: 2949-2951, 2005
67. Richardson PG, Blood E, Mitsiades CS, Jagannath S, Zeldenrust SR, Alsina M, Schlossman RL, Rajkumar SV, Desikan KR, Hideshima T, Munshi NC, Kelly-Colson K, Doss D, McKenney ML, Gorelik S, Warren D, Freeman A, Rich R, Wu A, Olesnyckyj M, Wride K, Dalton WS, Zeldis J, Knight R, Weller E, Anderson KC: A randomized phase 2 study of lenalidomide therapy for patients with relapsed or relapsed and refractory multiple myeloma. *Blood* July 18, 2006 [epub ahead of print]
68. Rajkumar SV, Hayman SR, Lacy MQ, Dispenzieri A, Geyer SM, Kabat B, Zeldenrust SR, Kumar S, Greipp PR, Fonseca R, Lust JA, Russell SJ, Kyle RA, Witzig TE, Gertz MA: Combination therapy with lenalidomide plus dexamethasone (Rev/Dex) for newly diagnosed myeloma. *Blood* 106: 4050-4053, 2005
69. Richardson PG, Barlogie B, Berenson J, Singhal S, Jagannath S, Irwin D, Rajkumar SV, Srkalovic G, Alsina M, Alexanian R, Siegel D, Orlowski RZ, Kuter D, Limentani SA, Lee S, Hideshima T, Esseltine DL, Kauffman M, Adams J, Schenkein DP, Anderson KC: A phase 2 study of bortezomib in relapsed, refractory myeloma. *N Engl J Med* 348: 2609-2617, 2003
70. Richardson PG, Sonneveld P, Schuster MW, Irwin D, Stadt-

- mauer EA, Facon T, Harousseau JL, Ben-Yehuda D, Lonial S, Goldschmidt H, Reece D, San-Miguel JF, Blade J, Boccardo M, Cavenagh J, Dalton WS, Boral AL, Esseltine DL, Porter JB, Schenkein D, Anderson KC: Bortezomib or high-dose dexamethasone for relapsed multiple myeloma. *N Engl J Med* 352: 2487–2498, 2005
71. Sanchorawala V, Wright DG, Rosenzweig M, Finn KT, Fennessey S, Zeldis JB, Skinner M, Seldin DC: Lenalidomide and dexamethasone in the treatment of AL amyloidosis: Results of a phase II trial. *Blood* 2006, in press
72. Palha JA, Ballinari D, Amboldi N, Cardoso I, Fernandes R, Bellotti V, Merlini G, Saraiva MJ: 4'-Iodo-4'-deoxydoxorubicin disrupts the fibrillar structure of transthyretin amyloid. *Am J Pathol* 156: 1919–1925, 2000
73. Sebastiao MP, Merlini G, Saraiva MJ, Damas AM: The molecular interaction of 4'-iodo-4'-deoxydoxorubicin with Leu-55Pro transthyretin 'amyloid-like' oligomer leading to disaggregation. *Biochem J* 351:273–279, 2000
74. Merlini G, Ascari E, Amboldi N, Bellotti V, Arbustini E, Perfetti V, Ferrari M, Zorzoli I, Marinone MG, Garini P, Diegolis M, Trizio D, Ballinari D: Interaction of the anthracycline 4'-iodo-4'-deoxydoxorubicin with amyloid fibrils: Inhibition of amyloidogenesis. *Proc Natl Acad Sci U S A* 92: 2959–2963, 1995
75. Gianni L, Bellotti V, Gianni AM, Merlini G: New drug therapy of amyloidoses: Resorption of AL-type deposits with 4'-iodo-4'-deoxydoxorubicin. *Blood* 86: 855–861, 1995
76. Gertz MA, Lacy MQ, Dispenzieri A, Cheson BD, Barlogie B, Kyle RA, Palladini G, Geyer SM, Merlini G: A multicenter phase II trial of 4'-iodo-4'-deoxydoxorubicin (IDOX) in primary amyloidosis (AL). *Amyloid* 9: 24–30, 2002
77. Pepys MB, Rademacher TW, Amatayakul-Chantler S, Williams P, Noble GE, Hutchinson WL, Hawkins PN, Nelson SR, Gallimore JR, Herbert J, Hutton T, Dwek RA: Human serum amyloid P component is an invariant constituent of amyloid deposits and has a uniquely homogeneous glycostructure. *Proc Natl Acad Sci U S A* 91: 5602–5606, 1994
78. Tennent GA, Lovat LB, Pepys MB: Serum amyloid P component prevents proteolysis of the amyloid fibrils of Alzheimer disease and systemic amyloidosis. *Proc Natl Acad Sci U S A* 92:4299–4303, 1995
79. Pepys MB, Herbert J, Hutchinson WL, Tennent GA, Lachmann HJ, Gallimore JR, Lovat LB, Bartfai T, Alanine A, Hertel C, Hoffmann T, Jakob-Roetne R, Norcross RD, Kemp JA, Yamamura K, Suzuki M, Taylor GW, Murray S, Thompson D, Purvis A, Kolstoe S, Wood SP, Hawkins PN: Targeted pharmacological depletion of serum amyloid P component for treatment of human amyloidosis. *Nature* 417: 254–259, 2002
80. Hussein MA, Juturi JV, Rybicki L, Lutton S, Murphy BR, Karam MA: Etanercept therapy in patients with advanced primary amyloidosis. *Med Oncol* 20: 283–290, 2003
81. Hrcic R, Wall J, Wolfenbarger DA, Murphy CL, Schell M, Weiss DT, Solomon A: Antibody-mediated resolution of light chain-associated amyloid deposits. *Am J Pathol* 157: 1239–1246, 2000